

# Proof of Principle: human histologic demonstration of socket healing with socket shield and grafting using non-demineralized autologous tooth dentin graft

Snježana Pohl<sup>1,2</sup>, Narayan Tondikulam Venkataraman<sup>3</sup>, Jelena Tomac<sup>4</sup>

<sup>1</sup>Department of Oral Medicine and Periodontology, University of Rijeka, Croatia. <sup>2</sup>Private Practice, Rijeka, Croatia. <sup>3</sup>Private Practice, Bangalore, India. <sup>4</sup>Department of Histology and Embryology, University of Rijeka, Croatia.

## Abstract

**Aim:** Human histologic evidence for the healed socket with socket shield has not yet been available. This clinical report aims to provide histological data of socket with socket shield and grafted with non-demineralized autologous tooth dentin graft 16 weeks after the first surgery.

**Materials and Methods:** A socket shield with adjacent hard tissue was retrieved using a hollow trephine four months after the socket shield preparation and socket grafting with non-demineralized dentin autograft. The tissue was submitted for histological analysis.

**Results:** The hard tissue composed of new bone, in direct contact with the residual dentin graft particles, filled the socket. Fibrovascular stroma was interposed between the dentin autograft embedded in the new bone and the lingual aspect of the socket shield surface. Unlike the buccal side, the polarized light microscopy confirmed the lack of cementum, periodontal ligament, and Sharpey's fibers on the lingual side of the shield. Intimate contact of bone to the shield was evident on the apical end.

**Conclusion:** Non-demineralized dentin autograft may prevent soft tissue ingrowth along the lingual socket shield surface. A thin layer of fibrovascular stroma was interposed between the new bone with residual dentin particles and the lingual socket shield surface.

**Keywords:** *Socket shield, Histology, Autologous dentin, Bone Graft.*

## Introduction

After tooth extraction, the loss of the periodontal ligament (PDL) and the marginal gingiva's cellular and fibrous attachment to root cementum induces bundle bone resorption (Araújo and Lindhe, 2005; Araújo *et al.*, 2015; Binderman *et al.*, 2002).

Most studies have demonstrated that the extraction socket grafting by various biocompatible and osteoconductive materials and/or use of occlusive barrier membranes minimize alveolar bone loss at the extraction site during the repair phase of wound healing (Avila-Ortiz *et al.*, 2019; Troiano *et al.*, 2018). In a radiographic cone-beam computed tomography study performed on 56 post-extraction sockets grafted with non-demineralized

autologous tooth dentin graft (ND-ATDG), four months after grafting, the reported reduction in the buccal bone plate thickness 1 mm, 3 mm, and 5 mm below the buccal crest was  $-0.87 \pm 0.84$  mm,  $-0.60 \pm 0.70$  mm, and  $-0.41 \pm 0.55$  mm, respectively (Pohl *et al.*, 2020). This data is according to the previously published human pilot study that compared dimensional ridge changes after tooth extraction either grafted with an ND-ATDG or without grafting (Canto-Díaz *et al.*, 2018).

While different techniques and grafting materials may limit the resorption of the buccal bone, no single material can completely compensate for post-extraction dimensional loss (Willenbacher *et al.*, 2016).

The retention of roots to preserve alveolar bone as a successful measure to maintain the denture-supporting tissue was introduced in the 1960s and 1970s (Bjorn, 1961; Guyer, 1975; Casey and Laucello, 1980).

---

Correspondence to: Snježana Pohl  
E-mail: snjezana.pohl@rident.hr

Salama *et al.*, (2007) submerged the root below implant-supported fixed prosthesis.

Hürzeler *et al.*, (2010) proposed to retain the buccal facet of the tooth root being firmly attached to the buccal bundle bone by PDL and marginal gingiva, socket shield (SS). An implant is placed immediately, or in the cases with contraindication for immediate implant placement, delayed (Glocker *et al.*, 2014).

Whereas there is evidence in the literature that SS may prevent the loss of the facial bone (Bäumer *et al.*, 2017; Mitsias *et al.*, 2020), little is known about socket healing in the presence of SS.

Pohl *et al.*, (2021), referred to clinical findings in 34 sockets with SS, either non-grafted or grafted with autologous materials. Soft tissue ingrowth along the lingual SS surface was common, except for sockets grafted with ND-ATDG or cortical tuberosity bone plate. Hard tissue, impenetrable by a periodontal probe, was reported in 5 sockets with SS, grafted with mineralized allograft particles (Shadid, 2022).

The aim of this clinical report was to provide histological data of ND-ATDG grafted socket with SS, 16 weeks after the first surgery.

### Case report

A 64-year-old Caucasian patient presented with periodontally and endodontically compromised hopeless teeth (Figure 1). A fixed prosthetic implant-based full arch rehabilitation was planned.

All teeth, except the maxillary right second premolar, were extracted following full-thickness mucoperiosteal buccal flap elevation. The socket shield procedure was performed for the maxillary second premolar on the right, as described by Gluckman *et al.* (2020).

Briefly, after the crown dissection, the root was dissected in a mesiodistal direction. The palatal root part, apex, and root canal content were removed, and the facial root fragment thinned to 1,5 mm. The coronal aspect of the socket shield was further thinned out.

Following extractions, inflammatory tissue was thoroughly debrided. During debridement and socket shield preparation was performed, the assistant processed the extracted non-endodontically treated teeth for ND-ATDG and the patient's blood to Platelet Rich Fibrin (PRF) membranes, according to manufacturer recommendations (Binderman *et al.*, 2014; Fujioka-Kobayashi *et al.*, 2017). A high-speed carbide bur was utilized to clean the teeth and remove calculus, filling materials, decay, and periodontal ligament. The teeth were dried by an air syringe and ground with the dedicated autologous tooth grinding device (Smart Dentin Grinder™, KometaBio Inc., Cresskill, NJ, USA). Particles with 300–1200 μm size were collected. Organic remnants and bacteria were dissolved with a basic alcohol cleanser, and the particulate was washed twice with phosphate-buffered saline.

Peripheral venous blood was collected in sterile vials and centrifuged to prepare plasma-rich fibrin (PRF)

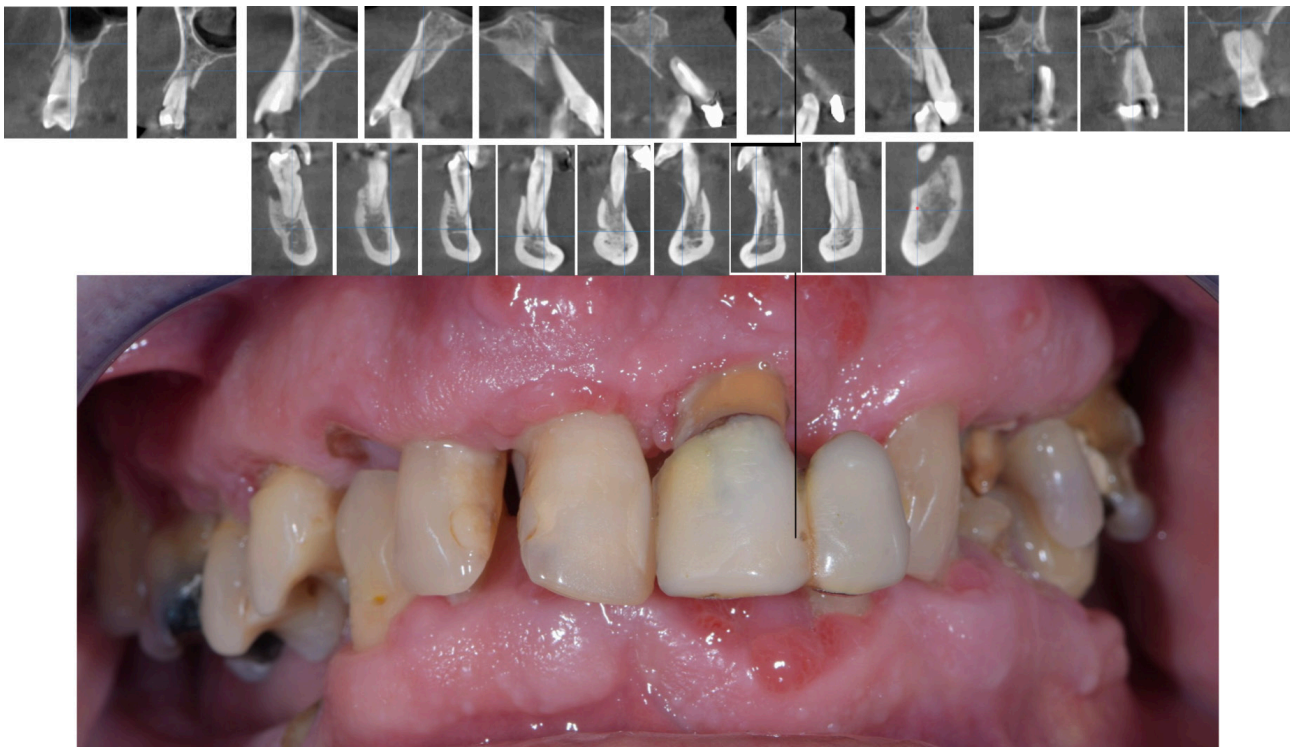


Figure 1. Cone-beam computed tomography (CBCT) cross-section scans (a) and intraoral photography (b) presenting seriously compromised teeth.

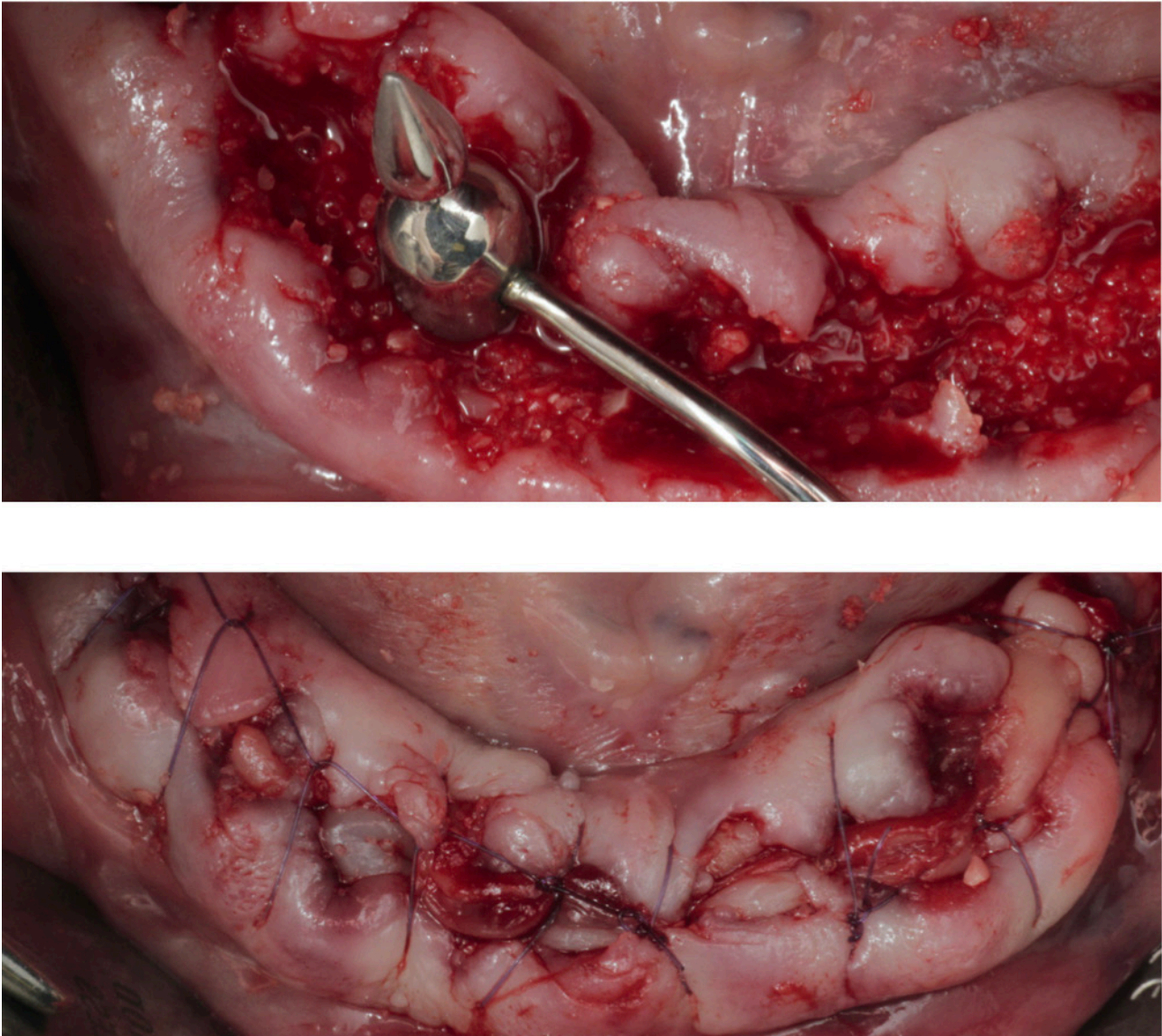
according to the slow centrifugation protocol at 1300 RPM for 8 minutes in the PRF DUO centrifuge. PRF membranes were pressed in a PRF box after blood centrifugation.

Extraction sockets and defects were filled with ND-ATDG and sealed with PRF membranes. Absorbable monofilament sutures 5.0 (Surgicryl Monofast, SMI, St. Vith, Belgium) were utilized to affix the PRF membrane over the grafted sockets. No effort was made to achieve the primary closure of the socket opening (Figure 2).

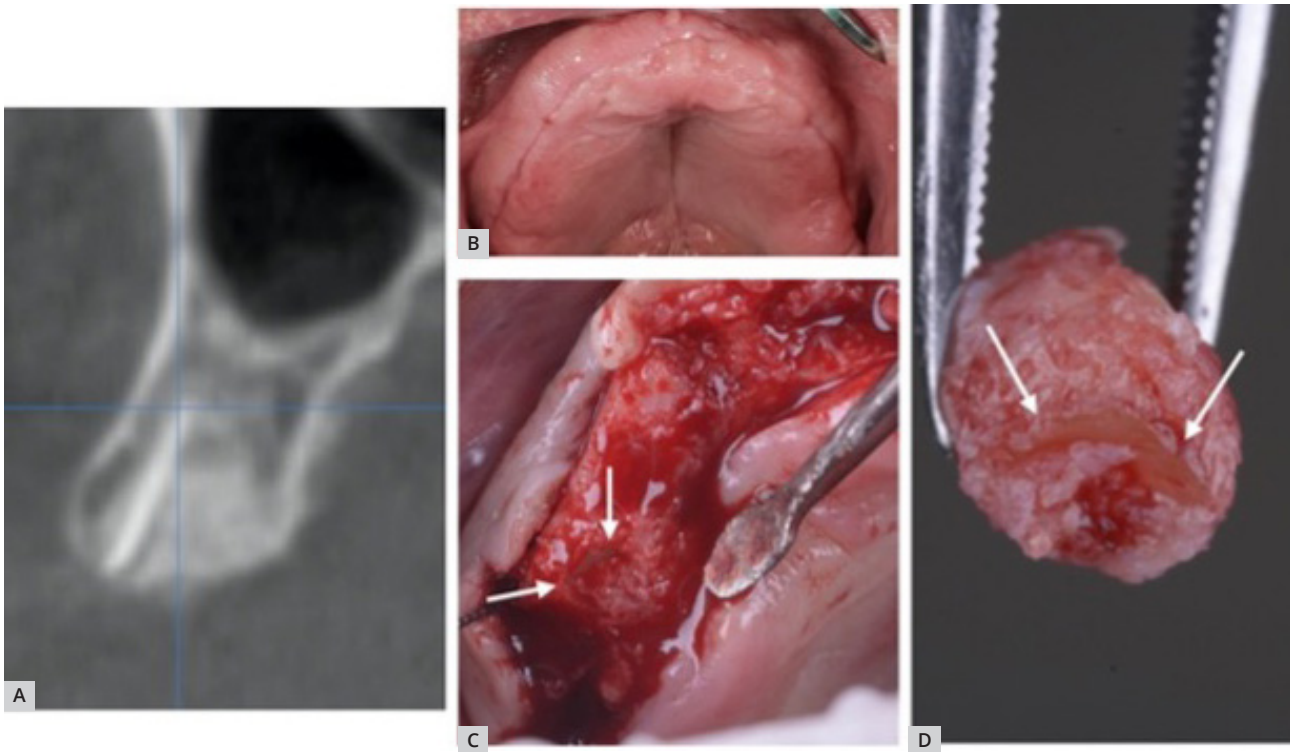
Four months after teeth extractions and grafting with ND-ATDG, the patient presented for implant placement. The restorative dentist and patient made a joint decision to modify the treatment plan and provide the patient with a removable bar-supported overdenture. Cone-beam computed tomography (CBCT) scans

were done, and four implants in the area of the lateral incisors and first premolars were planned. To gain restorative space, ridge height reduction was performed (Figure 3). In the second premolar area, socket shield with adjacent hard tissue was retrieved using a hollow trephine. With the patient's written consent, this tissue was preserved in 10% neutral buffered formalin and submitted for histological analysis to the Department of Histology and Embryology Faculty of Medicine, University of Rijeka.

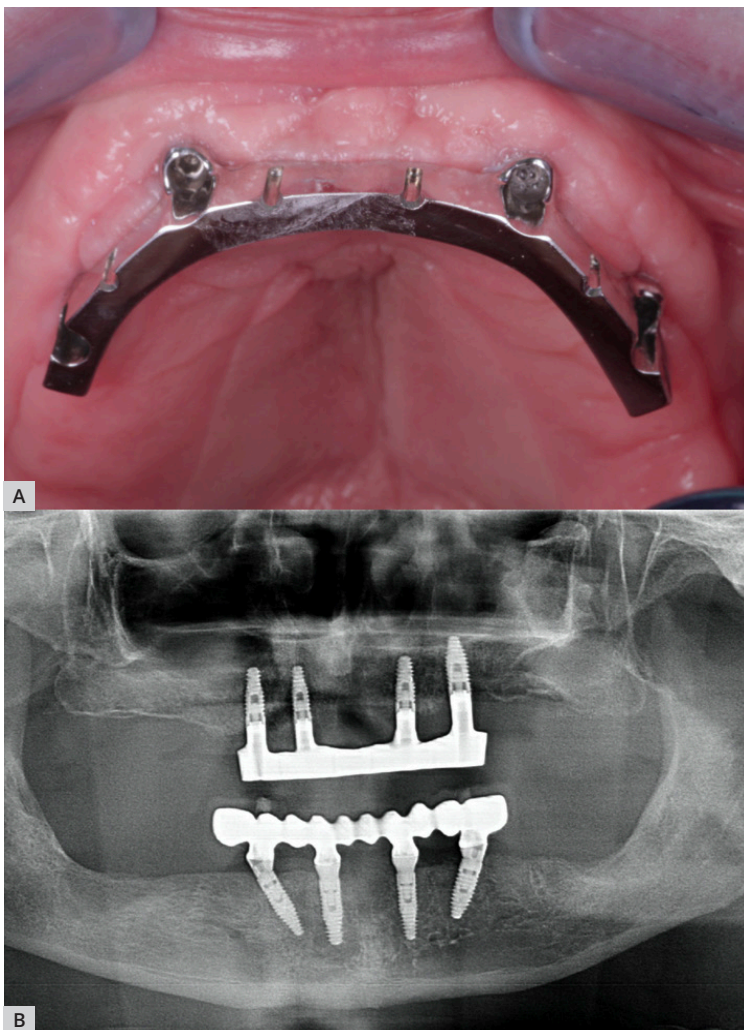
BEGO Semados RSX implants (BEGO Implant Systems, Bremen, Germany) were placed and left to heal subgingivally. After implant osseointegration, the patient was provided with the removable bar-supported overdenture in the upper and fixed implant-supported bridge in the low jaw (Figure 4).



**Figure 2.** Post-extraction sockets were grafted with ND-ATDG, and sockets were covered with PRF membranes.



**Figure 3.** CBCT scan shows well-integrated SS (a). Hard and soft tissue are well maintained (b). Ridge before vertical reduction, arrows are pointing to the socket shield (c). Core contains SS with surrounding bone (d).



**Figure 4.** Clinical situation one year after the implant placement. Peri-implant tissue appears healthy (a), radiograph shows stable crestal bone (b).

## Histologic Examination

The tissue was taken for processing 4 months later on account of the closure of the institute due to the Covid 19.

The tissue samples were fixed in 10% formalin, decalcified in Osteodec (Bio-Optica, Milan, Italy, Cat# 05-MO3005), and embedded in paraffin according to the standard procedures. Microtome sections (3 µm) were cut longitudinally and subjected to histological analysis.

The histology of the dental and bone tissues was qualitatively evaluated on the hematoxylin and eosin (H&E)-stained slides (Termo Fischer Scientific, Runcorn, UK).

Additional sections were subjected to Picrosirius red staining to evaluate the collagen fiber orientation and detect any cementum formation on the lingual aspect of the shield (Sigma-Aldrich, St.Louis, Missouri, USA, Cat# 365548).

Slides were analyzed on an Olympus BX51-P polarizing microscope, and images were acquired by Olympus digital camera DP71 (Tokyo, Japan).

Olympus software Cell B was utilized to measure the depth of soft tissue ingrowth.

## Results

Healing after extractions with socket grafting was uneventful. At re-entry 4 months after the first surgery, the socket shield in the second premolar area appeared firmly integrated into the hard tissue, except for the most coronal part of SS, which did not have any tissue in intimate contact. This most coronal soft tissue, covering the underlying hard tissue, was elevated in the flap.

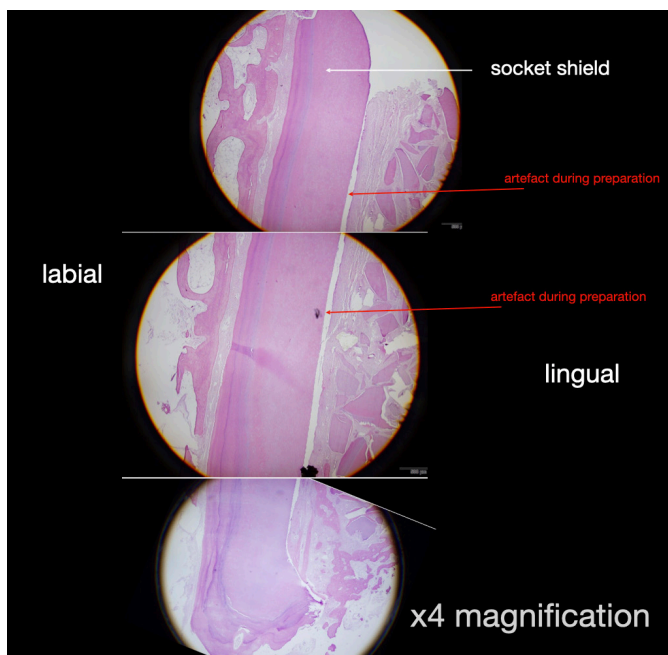
The light microscopy examination of the sectioned and H&E stained core revealed the intact root fragment with acellular cementum on the coronal and middle third and cellular cementum on the apical third of the labial aspect of the shield attached to a well preserved and defined periodontal ligament. There was no evidence of osteoclastic resorption of the inner aspect of the facial plate of bone, indicating that the bundle bone resorption had been prevented. On the lingual aspect of the shield, a fibrovascular stroma was interposed between the dentin autograft embedded in new bone and the lingual SS surface, which did not seem to show a PDL-like arrangement (Figure 5).

The most coronal part of the socket showed a dead space of 1.27 µm, corresponding to the soft tissue elevated in the flap that was covering the top of the socket (Figure 6).

There was evidence of bone formation in intimate contact with the graft particles, and the bone formation seems to extend into the fibrovascular stroma and in areas lying adjacent to the SS itself (Figures 7 and 8). The bone formation was most pronounced on the apical aspect of the socket, progressing coronally, with intimate contact between bone and SS apically (Figure 9).

A small gap was noticed between the shield's inner aspect and the fibrovascular tissue. This appears to be a processing & sectioning artifact due to the prolonged storage period before processing, causing separation of the grafted material from the inner aspect of the shield (Figures 5 and 7).

These findings were confirmed in the Picrosirius red-stained sections. The polarised light microscopy confirmed the lack of cementum, PDL, and Sharpey's fibers on the lingual side of the shield, unlike on the buccal side. The intimate contact of bone to the shield is also evident on the apical end (Figures 10 and 11).



**Figure 5.** Sections of socket shield with belonging buccal bone and grafted socket area x4 magnified and put together.

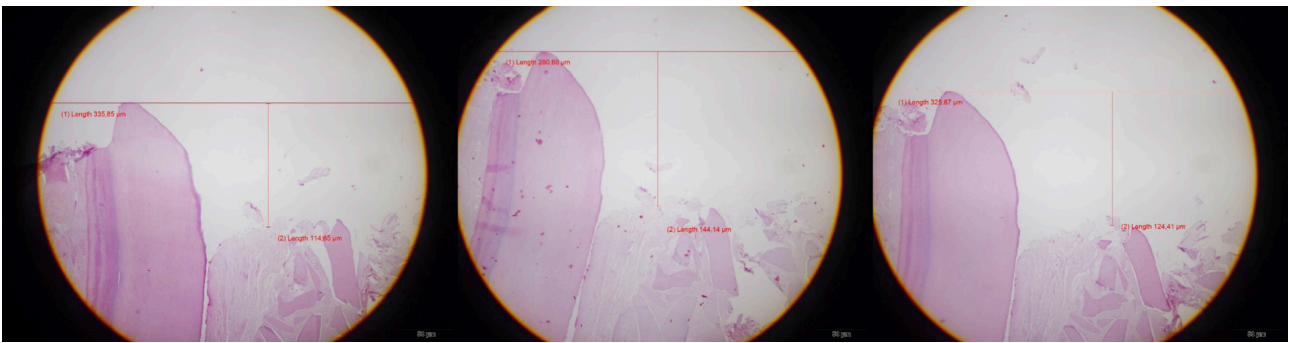


Figure 6. Histomorphometry to measure the depth of soft tissue ingrowth.

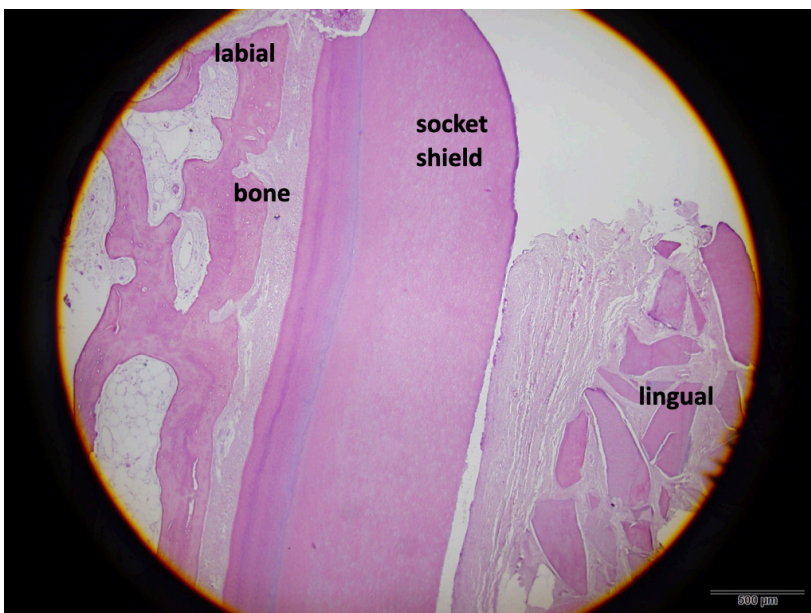


Figure 7. Higher magnification (x 4) of the coronal part.

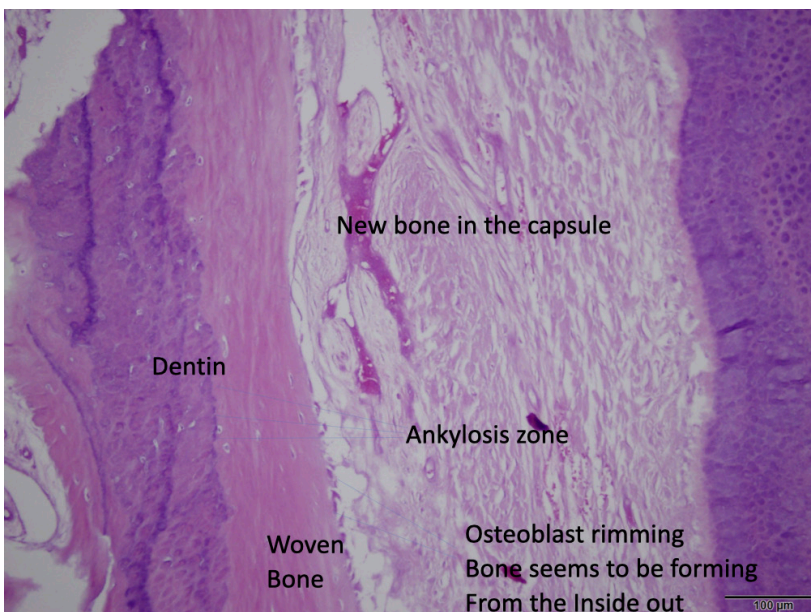
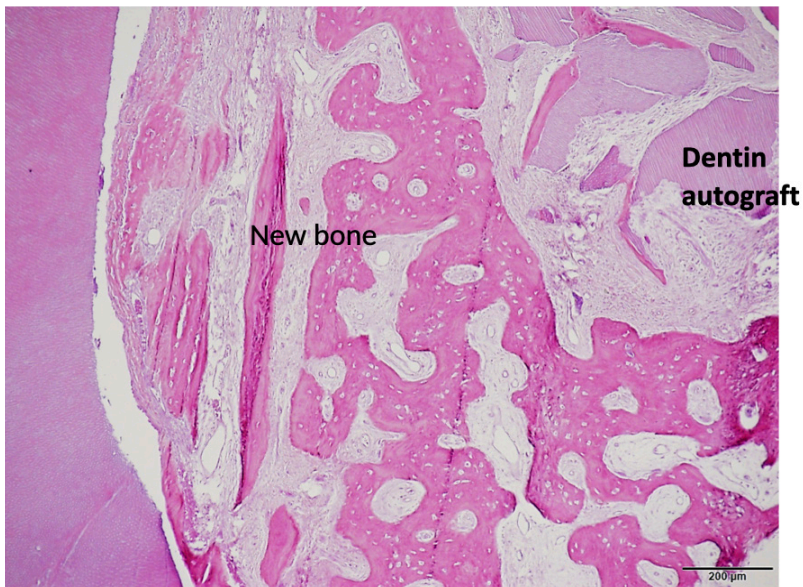
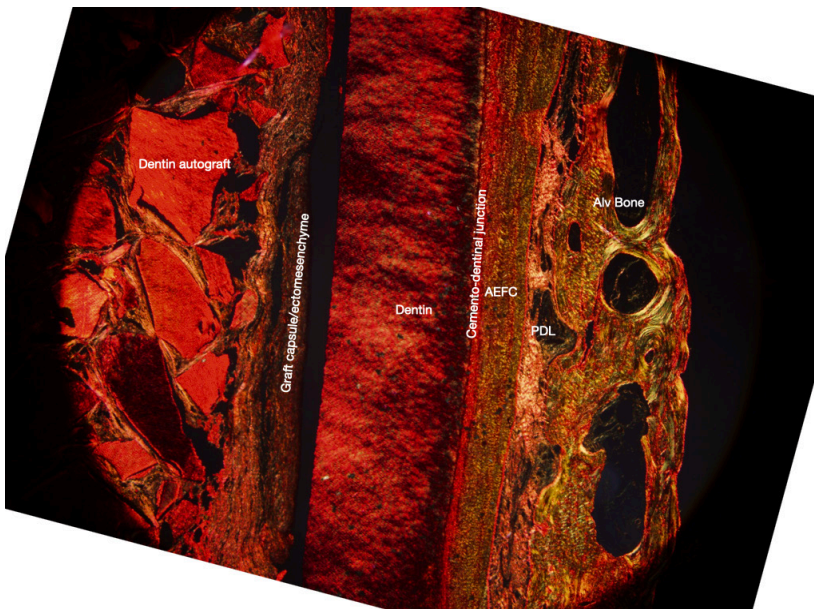


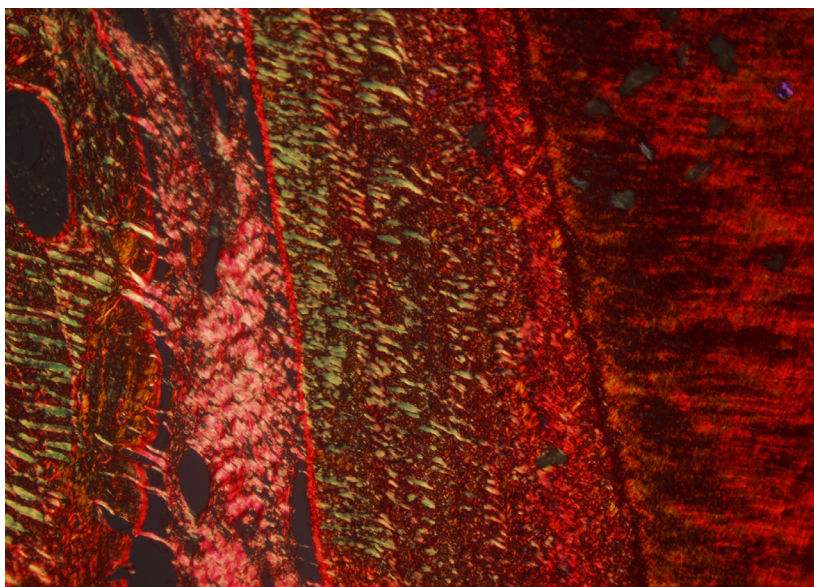
Figure 8. High magnification (x 20) depicting new bone in direct contact with ND-ATDG particle and new bone-forming inside the fibrous tissue along the lingual SS surface.



*Figure 9. The apical part magnified 10x. The new bone is in direct contact with the socket shield.*



*Figure 10. Picosirius red-stained sections showing cementum and PDL on the buccal site, and of cementum and PDL on the lingual socket shield site.*



*Figure 11. Polarized light microscopy showing extrinsic fibers of acellular cementum and Sharpey`s fibers in the buccal alveolar bone.*

## Discussion

There is evidence in the literature that SS may prevent the loss of the facial bone (Bäumer *et al.*, 2017; Mitsias *et al.*, 2020). The maintained PDL on the facial SS surface provides the buccal bundle bone and supracrestal soft tissue with the blood supply. In the present histologic examination, PDL on the buccal SS surface was maintained. The extrinsic fibers of the acellular cementum and Sharpey's fibers in the alveolar bone are amply demonstrated in polarized light microscopy. There were no signs of the shield resorption neither on the buccal nor on the lingual aspect. This is in accordance with the human histologic examination of the implant with SS, which does not show any SS resorption after 2 and 5 years of function (Mitsias *et al.*, 2017, Schwimer *et al.*, 2018).

Newly formed cementum (Hürzeler *et al.*, 2010) and bone (Bäumer *et al.*, 2013) were shown to fill the space between implant and SS in animal studies. Cementum formed along the lingual shield surfaces that were treated with enamel matrix derivate. In both animal studies, implants were placed in direct contact with the buccal root segments. This is in direct contrast to our sample, where there is no demonstrable cementum on the lingual aspect of the shield under polarized light microscopy.

Bone was found in the implant's interthread spaces in human histology of unintentionally retained SS (Schwimer *et al.*, 2018) where the implant was placed in contact with SS. A similar finding was reported for the implant with SS, retrieved after 5 years of function: the implant's interthread spaces were filled with the bone in the area of the direct implant-SS contact (Mitsias *et al.*, 2017). However, connective tissue without any inflammatory infiltrate was present in the coronal portion, where a gap was left between the implant and SS. Other histological studies with implants placed at a distance from SS are not yet available. Our histology demonstrates a close approximation of bone to the SS on the lingual aspect; however, since no implant has been placed, a direct comparison cannot be drawn between these histological studies. It can only be hypothesized that as socket healing progresses with the ND-ATDG, (as described later in this discussion), any future implant placement should result in the bone between the threads of the implant.

Clinical observation in sockets with SS and delayed implant placement is that the internal bone fill is often unsatisfactory, with a soft tissue ingrowth along the lingual SS surface. Although not mentioned in the first case series report to sockets with SS and delayed implant placement, the soft tissue invagination along the lingual SS surface can be observed in clinical images (Glocker *et al.*, 2014). Sockets were filled with collagen sponge with an integrated collagen membrane.

It was reported that socket grafting with autologous materials with a slow turnover rate and mineralized allograft particles might prevent this soft tissue ingrowth (Pohl *et al.*, 2021; Shadid, 2022).

The aforementioned retrospective assessment of 34 human post-extraction sockets with SS (Pohl *et al.*, 2021) reported soft tissue ingrowth along the inner surface of the root fragment, consequently resulting in less bone fill for sockets left to heal with a blood clot only or filled with PRF plugs, or autologous bone particles. One possible explanation is that SS prevents bone ingrowth from the buccal bone wall, and soft tissue from the marginal border of the socket occupies the space. The hard tissue in sockets previously grafted with ND-ATDG or cortical tuberosity bone plates was not penetrable for the periodontal probe. In a case series of five sockets with SS, mineralized allograft as grafting material, and delayed implant placement, 1 mm soft tissue ingrowth was reported in 4 sockets and 3 mm in one socket (Shadid, 2022). Mineralized allograft, ND-ATDG, and cortical tuberosity bone plate have a slow turnover rate in common, which seems to prevent soft tissue invagination. Still, without histological analysis, this hard tissue's composition was hitherto unknown. To the best of our knowledge, this is the first study to describe the nature of this tissue histologically.

Dentin and bone contain a similar percentage of collagen and hydroxylapatite (Brudevold *et al.*, 1980). Dentin and cementum contain proteins in common with bone, such as osteopontin, osteocalcin, bone sialoprotein, dentin matrix protein, and collagen type I (Linde, 1989). Dentin also contains bone morphogenetic proteins (BMPs), insulin-like growth factor (IGF)-II, and transforming growth factor (TGF)- $\beta$  (Finkelman *et al.*, 1990). The present histologic examination verifies that the hard tissue consists of newly formed bone in intimate contact with residual ND-ATDG particles ND-ATDG is shown to induce a new bone deposition directly on its surface, like ankylosis, and new bone is regularly observed, with replacement resorption of most dentin particles 3,5 months after grafting (Andrade *et al.*, 2019; Mazor *et al.*, 2019; van Orten *et al.*, 2022). It was shown that mineralized dentin particles present intra- and inter-particle porosity, which results in up to three times larger volume of tooth matter after grinding (Calvo-Guirado *et al.*, 2019). This porosity increases space for new vessel growth, supporting healing and replacement resorption to achieve lamellar bone. The turnover of the graft particle seems to follow an apical-coronal and core-periphery pattern. Areas of the examined sections show close apposition of bone on the inner aspect of the shield. At the apical end of the shield, where the peripheral bone turnover is complete, the bone lies directly on the shield. It is possible that the well-maintained and functioning



PDL on the buccal SS aspect can explain the presence of fibrovascular tissue along the lingual SS surface. Histological study of submerged roots with intact PDL shows connective tissue continuously separating the coronal dentin and new bone formation (O'Neal *et al.*, 1978). The width of the fibrovascular tissue along the lingual SS surface was similar to PDL thickness, and this area cannot be probed with the periodontal probe. A dead space in the most coronal portion of the root fragment was not reported in the previously published case series report (Pohl *et al.*, 2021). In this patient's case, it could be explained by movement and graft displacement caused by the removable, mucosa-supported overdenture.

The aforementioned case series report showed that autologous materials with a short turnover time do not prevent soft tissue ingrowth in the sockets with SS (Pohl *et al.*, 2021). The turnover time of ND-ATDG is long, this biomaterial has osteoconductive properties, and dentin demineralization during remodeling by osteoclasts confers osteopromotive effects (Schwartz *et al.*, 2000). Demineralized dentin promotes osteoblastic proliferation and early differentiation via TGF- $\beta$ 1 transduction (Begue-Kirn *et al.*, 1992) which may explain dentin particles being foci of new bone formation.

The healing dynamics of ND-ATDG is well aligned with implant osseointegration dynamics. Histomorphometric analysis of an osseointegrated implant placed in healed ND-ATDG grafted site has demonstrated 75% bone-to-implant contact 4 months after the implant placement, with scarce residual dentin particles that were not in contact with the implant (Pohl *et al.*, 2022). Histomorphometric analysis of 66 sites following ND-ATDG or xenograft post-extraction socket grafting showed a significantly higher quantity of newly formed bone and a lower amount of residual graft for dentin-grafted sockets (Santos *et al.*, 2021).

Furthermore, it is confirmed that a human PDL fibroblast cell line shows a very promising growth reaction to the mineralized dentin in vitro (Bernardi *et al.*, 2019).

Post-extraction sockets grafted with ND-ATDG do not require a primary wound closure. Socket opening closure with PRF membrane or collagenous sponge to contain granule is sufficient.

Healing pattern may differ when an implant is placed at the same time, particularly when a customized, occlusive healing abutment or provisional crown is inserted. Studies from researcher teams that differ with regard to the distance between the implant and SS and grafting the gap show implant survival rates similar to the implants placed without SS and better preservation of the peri-implant hard and soft tissue for SS implant sites (Kotsakis. *et al.*, 2022).

To the best of our knowledge, this is the first such report of human histology demonstrating socket healing with a socket shield. It shows both the ability of the socket shield to prevent bundle bone resorption as well as the viability of PDL and marginal gingiva and the utility of autologous dentin as a graft material to prevent soft tissue down growth between the socket shield and the bone, thus optimizing the bone regeneration for ideal positioning of an implant in the preserved ridge.

While the limitation of this report is that it presents a histological analysis of one single site, it could serve as the scaffold for building well-designed RCTs to analyze the dynamics of socket healing histologically after SS & different graft materials.

## References

- Andrade C, Camino J, Nally M et al. Combining autologous particulate dentin, L-PRF, and fibrinogen to create a matrix for predictable ridge preservation: a pilot clinical study. *Clinical Oral Investigations* 2020; **24**:1151–1160.
- Araújo MG and Lindhe J. Dimensional ridge alterations following tooth extraction. An experimental study in the dog. *Journal of Clinical Periodontology* 2005; **32**:212-218.
- Araújo MG, Silva CO, Misawa M and Sukekava F. Alveolar socket healing: what can we learn? *Periodontology* 2000 2015; **68**:122–134.
- Avila-Ortiz G, Chambrone L and Vignoletti F. Effect of alveolar ridge preservation interventions following tooth extraction: A systematic review and meta-analysis. *Journal of Clinical Periodontology* 2019; **46**:195-223.
- Bäumer D, Zuhr O, Rebele S, Schneider D, Schupbach P, Hürzeler M. The socket-shield technique: first histological, clinical, and volumetric observations after separation of the buccal tooth segment – a pilot study. *Clinical implant dentistry and related research* 2015; **17**:71-82.
- Bäumer D, Zuhr O, Rebele S and Hürzeler M. Socket Shield Technique for immediate implant placement - clinical, radiographic and volumetric data after 5 years. *Clinical Oral Implants Research* 2017; **28**:1450-1458.
- Begue-Kirn C, Smith AJ, Ruch JV, et al. Effects of dentin proteins, transforming growth factor beta 1 (TGF beta 1) and bone morphogenetic protein 2 (BMP2) on the differentiation of odontoblast in vitro. *The International journal of developmental biology* 1992; **36**:491-503.
- Bernardi S, Mummolo S, Varvara G et al. Biomorphological evaluation of periodontal ligament fibroblasts on mineralized dentin graft: an in vitro study. *Journal of Biological Regulators and Homeostatic Agents* 2019; **33**:275-280.

- Binderman I, Bahar H and Yaffe A. Strain relaxation of fibroblasts in the marginal periodontium is the common trigger for alveolar bone resorption: a novel hypothesis. *Journal of Periodontology* 2002; **73**:1210-1215.
- Binderman I, Hallel G, Nardy C, Yaffe A and Sapoznikov L. A novel procedure to process extracted teeth for immediate grafting of autogenous dentin. *Journal of Interdisciplinary Medicine and Dental Science* 2014; **2**:2.
- Bjorn H. Experimental studies on reattachment. *Dental Practice* 1961; **11**:451-454.
- Brudevold F, Steadman LT and Smith F A. Inorganic and organic components of tooth structure. *Annals of the New York Academy of Sciences* 1980; **85**:110-132.
- Calvo-Guirado JL, Ballester-Montilla A, De Aza P et al. Particulated, Extracted Human Teeth Characterization by SEM(-)EDX Evaluation as a Biomaterial for Socket Preservation: An in vitro Study. *Materials (Basel)* 2019; **12**:3.
- Canto-Díaz AD, Elío-Oliveros JD, Canto-Díaz MD, Alobera-Gracia MA, Canto-Pingarrón MD and Martínez-González JM. Use of autologous tooth-derived graft material in the post-extraction dental socket. Pilot study. *Medicina Oral Patología Oral y Cirugía Bucal* 2018; **24**: e53–e60.
- Casey DM and Lauciello FR. A review of the submerged-root concept. *Journal of Prosthetic Dentistry* 1980; **43**:128-132.
- Finkelman RD, Mohan S, Jennings JC, Taylor AK, Jepsen S and Baylink DJ. Quantitation of growth factors IGF-I, SGF/IGF-II, and TGF-beta in human dentin. *Journal of bone and mineral research* 1990; **5**:717–723.
- Fujioka-Kobayashi M, Miron RJ, Hernandez M, Kandaram U, Zhang Y and Choukroun J. Optimized platelet-rich fibrin with the low-speed concept: growth factor release, biocompatibility, and cellular response. *Journal of Periodontology* 2017; **88**:112-21.
- Glocker M, Attin T and Schmidlin P. Ridge preservation with modified “socket-shield” technique: a methodological case series. *Dentistry Journal* 2014; **2**:11-21.
- Gluckman H, Du Toit J, Salama M, Nagy K and Dard M. A decade of the socket-shield technique: a step-by-step partial extraction therapy protocol. *International Journal of Esthetic Dentistry* 2020; **15**:212-225.
- Guyer SE. Selectively retained vital roots for partial support of overdentures: A patient report. *Journal of Prosthetic Dentistry* 1975; **33**: 258–263.
- Hürzeler MB, Zühr O, Schupbach P, Rebele SF, Emmanouilidis N and Fickl S. The socket-shield technique: a proof-of-principle report. *Journal of Clinical Periodontology* 2010; **37**:855-862.
- Kotsakis GA, Nguyen TT, Siormpas K et al. Clinical outcomes of retention of the buccal root section combined with immediate implant placement: A systematic review of longitudinal studies. *Clinical implant dentistry and related research* 2022; **1**- 12.
- Linde, A. Dentin matrix proteins: Composition and possible functions in calcification. *The Anatomical Record* 1989; **224**:154–166.
- Mazor Z, Horowitz RA, Prasad H and Kotsakis GA. Healing Dynamics Following Alveolar Ridge Preservation with Autologous Tooth Structure. *International Journal of Periodontics and Restorative Dentistry* 2019; **39**:697-702.
- Mitsias ME, Siormpas KD, Kotsakis GA, Ganz SD, Mangano C and Iezzi G. The Root Membrane Technique: Human Histologic Evidence after Five Years of Function. *Biomed Research International* 2017; **2017**:7269467.
- Mitsias MM, Bratos M, Siormpas K, Pikos MA, Kotsakis GA and Root Membrane Group. Longitudinal Soft Tissue Changes During Periodontal Ligament-Mediated Immediate Implant Placement with the Root-Membrane Technique. *International Journal of Oral and Maxillofacial Implants* 2020; **35**:379-385.
- O’Neal RB, Gound T, Levin MP and del Rio CE. Submergence of roots for alveolar bone preservation. I. Endodontically treated roots. *Oral Surgery Oral Medicine and Oral Pathology* 1978; **45**:803-10.
- Pohl S, Binderman I and Tomac J. Maintenance of Alveolar Ridge Dimensions Utilizing an Extracted Tooth Dentin Particulate Autograft and Platelet-Rich fibrin: A Retrospective Radiographic Cone-Beam Computed Tomography Study. *Materials* 2020; **13**:1083.
- Pohl S, Binderman I, Božić D, Shapira L and Venkataraman NT. Effectiveness of Autologous Tissue Grafts on Soft Tissue Ingrowth in Patients Following Partial Root Extraction with Socket Shield: A Retrospective Analysis of a Case Series. *International Journal of Oral and Maxillofacial Implants* 2021; **36**:362-370.
- Pohl S, Prasad H, Prasad S and Kotsakis G A. Human Histologic Analysis of Implant Osseointegration in a Healed Site Grafted with Nondemineralized Autologous Tooth-Derived Graft Material. *The International journal of periodontics & restorative dentistry* 2022; **42**, e199–e207.
- Salama M, Ishikawa T, Salama H, Funato A and Garber D. Advantages of the root submergence technique for pontic site development in esthetic implant therapy. *International Journal of Periodontics and Restorative Dentistry* 2007; **27**:521-527.

- Santos A, Botelho J, Machado V et al. Autogenous Mineralized Dentin versus Xenograft granules in Ridge Preservation for Delayed Implantation in Post-extraction Sites: A Randomized controlled clinical trial with an 18 months follow-up. *Clinical oral implants research* 2021; **32**:905–915.
- Schwartz Z, Lohmann C, Wieland M et al. Osteoblast Proliferation and Differentiation on Dentin Slices Are Modulated by Pretreatment of the Surface with Tetracycline or Osteoclasts. *Journal of Periodontology* 2000; **71**:586-597.
- Schwimer C, Pette GA, Gluckman H, Salama M and Du Toit J. Human Histologic Evidence of New Bone Formation and Osseointegration Between Root Dentin (Unplanned Socket-Shield) and Dental Implant: Case Report. *International Journal of Oral and Maxillofacial Implants* 2018; **33**:e19-e23.
- Shadid RM. Socket shield technique and delayed implant placement in maxilla: a series of five case reports. *BMC Oral Health* 2022; **22**,110.
- Troiano G, Zhurakivska K, Lo Muzio L, Laino L, Cicciù M and Lo Russo L. Combination of bone graft and resorbable membrane for alveolar ridge preservation: A systematic review, meta-analysis, and trial sequential analysis. *Journal of Periodontology* 2018; **89**:46-57.
- van Orten A, Goetz W and Bilhan H. Tooth-Derived Granules in Combination with Platelet-Rich Fibrin (“Sticky Tooth”) in Socket Preservation: A Histological Evaluation. *Dentistry journal* 2022; **10**:29.
- Willenbacher M, Al-Nawas B, Berres M, Kammerer PW and Schiegnitz E. The Effects of Alveolar Ridge Preservation: A Meta-Analysis. *Clinical Implant Dentistry and Related Research* 2016; **18**:1248-68.